

Positive Remodeling as a Biomarker of Plaque Vulnerability — at the Border between Invasive and Noninvasive Assessment

Tiberiu Nyulas¹, Mirabela Morariu¹, Monica Chițu¹, Alexandra Stănescu², Laura Jáni², Edvin Benedek², Daniel Cernica², Elisabeta Himcimschi², Annabell Benedek¹, Imre Benedek^{1,2}

¹University of Medicine and Pharmacy, Tîrgu Mureș, Romania

²Center of Advanced Research in Multimodality Cardiac Imaging, Cardio Med Medical Center, Tîrgu Mureș, Romania

CORRESPONDENCE

Alexandra Stănescu

Str. 22 Decembrie 1989 nr. 76
540124 Tîrgu Mureș, Romania
Tel: +40 265 217 333
E-mail: alexandrastanescu90@gmail.com

ARTICLE HISTORY

Received: 6 October, 2016
Accepted: 29 November, 2016

Tiberiu Nyulas • Str. Gheorghe Marinescu nr. 38,
540139 Tîrgu Mureș, Romania. Tel: +40 265 215 551.
E-mail: tiberiu.nyulas@gmail.com

Mirabela Morariu • Str. Gheorghe Marinescu nr. 38,
540139 Tîrgu Mureș, Romania. Tel: +40 265 215 551.
E-mail: mirabela.morariu@yahoo.com

Monica Chițu • Str. Gheorghe Marinescu nr. 38,
540139 Tîrgu Mureș, Romania. Tel: +40 265 215 551.
E-mail: iuliachitu@yahoo.com

Laura Jáni • Str. 22 Decembrie 1989 nr. 76, 540124
Tîrgu Mureș, Romania. Tel: +40 265 217 333. E-mail:
jlaura15@yahoo.com

Edvin Benedek • Str. 22 Decembrie 1989 nr. 76,
540124 Tîrgu Mureș, Romania. Tel: +40 265 217 333.
E-mail: edvinke87@gmail.com

Daniel Cernica • Str. 22 Decembrie 1989 nr. 76,
540124 Tîrgu Mureș, Romania. Tel: +40 265 217 333.
E-mail: daniel.cernica@gmail.com

Elisabeta Himcimschi • Str. 22 Decembrie 1989 nr.
76, 540124 Tîrgu Mureș, Romania. Tel: +40 265 217
333. E-mail: eli_himcimschi@yahoo.com

Annabell Benedek • Str. Gheorghe Marinescu nr. 38,
540139 Tîrgu Mureș, Romania. Tel: +40 265 215 551.
E-mail: annabell.benedek@yahoo.com

Imre Benedek • Str. Gheorghe Marinescu nr. 38,
540139 Tîrgu Mureș, Romania. Tel: +40 265 215 551.
E-mail: imrebenedek@yahoo.com

ABSTRACT

Since the introduction of the new concepts of plaque vulnerability and patient vulnerability, many researchers have focused on different biomarkers that can represent predictors for coronary plaque instability. One of the features that characterize the vulnerable coronary plaque is positive remodeling, which can be easily identified by computed tomography angiography, a noninvasive procedure, or by other invasive methods such as intravascular ultrasound. This review aims to describe the assessment of positive remodeling as a marker of coronary plaque instability and the differences between computed tomography angiography and intravascular ultrasound in investigating this new biomarker.

Keywords: computed tomography angiography, intravascular ultrasound, positive remodeling, vulnerable plaque

In the last decades, cardiac imaging tools have shown enormous development. Thus, from the simple echocardiography, the technology reached a level where the patient is examined with complex multimodal imaging procedures such as computed tomography angiography (CTA), intravascular ultrasound (IVUS), optical coherence tomography (OCT), or 3D echocardiography. The purpose of these imaging techniques is to increase diagnostic accuracy, establish a better approach and patient follow-up, and achieve accurate risk stratification. Despite the development of these imaging methods used to prevent and to decrease the incidence and mortality of ischemic heart diseases, according to the World Health Organization, ischemic heart disease is still the leading cause of mortality worldwide, with an incidence of 8.75%.¹

Acute coronary syndromes are part of ischemic heart disease and consist in the rupture of coronary plaques that leads to an acute cessation of blood flow.

Coronary plaques have been intensively studied by many researchers using imaging techniques to analyze the consistency, location, and functional impact of the stenosis caused by coronary plaques. Thus came the paradigm of the vulnerable plaque that is prone to rupture.²

Focusing on prevention is of great importance with regards to lowering the costs associated with the treatment of coronary patients, at the same time with decreasing the mortality caused by myocardial infarction. Hence, studying coronary plaques — even if not associated with a high degree of stenosis — may help in identifying vulnerable plaques with high instability degree that can rupture and cause acute coronary syndromes. The imaging techniques used in the assessment of coronary plaques can be invasive and noninvasive. There are advantages and disadvantages to both categories; there are studies stating that invasive imaging procedures provide a superior illustration of the coronary plaques, while other studies indicate the opposite. In order to examine vulnerable coronary plaques, it is necessary to identify the features that indicate a high level of instability, also known as vulnerability indicators.

Vulnerable plaques are characterized primarily by instability and a high risk of rupture, causing acute coronary syndromes. In 1985, Davies *et al.* identified the rupture-prone plaque as the cause of coronary thrombosis and described the role of increased state of inflammation in the progress of plaque instability.^{3,4}

In 1987, Seymour Glagov *et al.* described the concept of coronary remodeling after studying the left main arteries from 136 hearts obtained from autopsies. Based on histological analysis of the coronary sections, they identified a coronary enlargement in atherosclerotic arteries and named it compensatory enlargement of the coronary artery. They stated that the coronary lumen remains the same until plaque development extends to approximately 40% of the coronary circumference, when positive remodeling stops.⁵

In 2000, Virmani *et al.* identified erosions and calcifications as the mechanisms of thrombosis and associated vulnerable plaques with the presence of thin-cap fibroatheroma (TCFA).⁶ Other studies found that vulnerable coronary plaques have a TCFA that often has a necrotic core, positive remodeling, microcalcifications, and intra-plaque hemorrhages.⁷ TCFA was described to have a high degree of inflammation due to the pro-inflammatory cytokines secreted as a response to cholesterol crystals, leading to the occurrence of lesions in the fibrous cap.⁸

Positive remodeling, as an imaging marker of coronary plaques with high probability of rupture, has raised a lot of

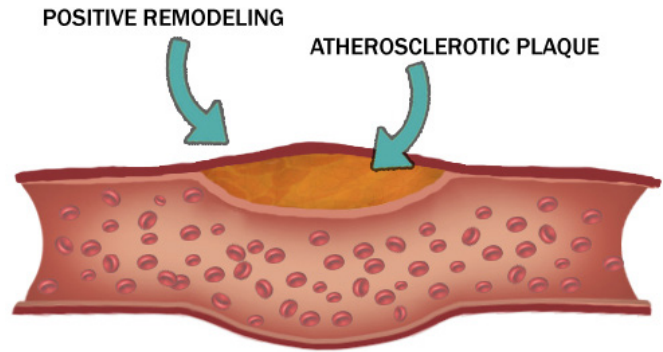


FIGURE 1. Illustration of an atherosclerotic plaque

questions regarding its mechanism of occurrence, but also regarding the best imaging method to study this feature.

As shown in Figure 1, there is an enlargement in the coronary artery that represents positive remodeling, a feature present in vulnerable plaques. It consists of a compensatory enlargement of the coronary wall, but also of the lumen, that precedes luminal narrowing. Davies *et al.* described this phenomenon as a compensatory mechanism, which has the role to decrease adverse events related to vessel obstruction.⁹

Burke *et al.* studied coronary plaques and stated that ruptured plaques had the highest remodeling index, followed by lesions with hemorrhage; they also observed that lesions with total occlusion presented negative remodeling.¹⁰

CORONARY COMPUTED TOMOGRAPHY ANGIOGRAPHY (CTA) — NONINVASIVE IMAGING

CTA represents a reliable method for the assessment of vulnerable coronary plaques, offering important details regarding plaque features such as the remodeling index and calcium detection.^{11,12} However, this noninvasive procedure cannot provide information regarding the thickness of the TCFA or the size of the necrotic core, nor the presence of inflammation at different sites.

Many researchers have used CTA in order to assess coronary plaques prone to rupture. Motoyama *et al.* studied the plaque remodeling index and the degree of attenuation of coronary plaques using CTA in 5 patients, and they observed that subjects who presented coronary plaques with a remodeling index higher than 1 and low attenuation lesions developed plaque ruptures during the follow-up period in comparison with patients whose coronary lesions did not present these features.¹³

Kröner *et al.* have evaluated vulnerable coronary plaques using both invasive and noninvasive methods. They found

that lesions with positive remodeling, identified on CTA, were associated with a higher prevalence of TCFA and a higher amount of necrotic core seen on virtual histology intravascular ultrasound (VH-IVUS).¹⁴

Similar results were found by Fuster *et al.* in their study, where the histological findings confirmed that vulnerable plaques presenting positive remodeling on CTA have a large necrotic core with macrophage infiltration.^{15,16}

Schmid *et al.* have shown the usefulness of CTA in the appraisal of unstable coronary plaques, thus offering a precise characterization of the compensatory enlargement of the vessel.¹⁷

INVASIVE APPROACH — COULD IT BE THE MOST PRECISE APPROACH?

One of the invasive methods used to describe coronary positive remodeling is IVUS, which became intensively studied recently. Being an invasive procedure, it involves certain risks that the clinician and the patient should consider, but also high costs. IVUS plays an important role in the assessment of coronary plaque morphology and characteristics, providing information about the arterial wall. Nissen *et al.* emphasized the potential benefit of IVUS: it is able to differentiate stable coronary plaques from those prone to rupture and provides information regarding vascular remodeling features.¹⁸

Yamagishi *et al.* studied the morphology of vulnerable coronary plaques using IVUS in 112 patients with chest pain and indication for coronary catheterization. They performed invasive angiocoronarography, and all coronary lesions with a stenosis smaller than 50% were examined with IVUS. Using the information offered by IVUS, they concluded that patients who experienced an acute coronary syndrome had an eccentric plaque distribution.¹⁹

Raffel *et al.* examined coronary plaques using IVUS and OCT and found that positive remodeling was associated with coronary plaques characterized by TCFA. This in vivo study showed the benefits of invasive imaging in detecting the positive remodeling feature of coronary vessels.²⁰

CONCLUSION

Positive remodeling represents an important feature of unstable coronary plaques, and its early detection can prevent the rupture of the plaque, avoiding an acute coronary syndrome. Both invasive and noninvasive techniques can assess this feature, thereby providing vital information regarding the coronary artery wall.

CONFLICT OF INTEREST

Nothing to declare.

ACKNOWLEDGEMENT

This research was supported via the research grant no. 103545/2016, contract number 43/05.09.2016, entitled “High performance multimodal MRI/CT imaging platform, for applications in computational medicine, nanoparticles and hybrid imaging for the research of atherothrombotic disorders – CARDIO IMAGE” financed by the Romanian Ministry of European Funds, the Romanian Government and the European Union.

REFERENCES

1. World Health Organization, Cardiovascular disease (CVDs), 2016. Available from: <http://www.who.int/mediacentre/factsheets/fs317/en/#>.
2. Finn AV, Nakano M, Narula J, Kolodgie FD, Virmani R. Concept of vulnerable/unstable plaque. *Arteriosclerosis, thrombosis, and vascular biology*. 2010;30:1282-1292.
3. Davies MJ, Thomas A. Thrombosis and acute coronary-artery lesions in sudden cardiac ischemic death. *N Engl J Med*. 1984;310:1137-1140.
4. Davies MJ. Stability and instability: two faces of coronary atherosclerosis: the Paul Dudley White Lecture 1995. *Circulation*. 1996;94:2013-2020.
5. Glagov S, Weisenberg E, Zarins CK, Stankunavicius R, Koletts GJ. Compensatory enlargement of human atherosclerotic coronary arteries. *N Engl J Med*. 1987;316:1371-1375.
6. Virmani R, Kolodgie FD, Burke AP, Farb A, Schwartz SM. Lessons from sudden coronary death: a comprehensive morphological classification scheme for atherosclerotic lesions. *Arterioscler Thromb Vasc Biol*. 2000;20:1262-1275.
7. Falk E, Nakano M, Bentzon JF, Finn AV, Virmani R. Update on acute coronary syndromes: the pathologists' view. *Eur Heart J*. 2013;34:719-728.
8. Kolodgie FD, Virmani R, Burke AP, et al. Pathologic assessment of the vulnerable human coronary plaque. *Heart*. 2004;90:1385-1391.
9. Davies MJ, Thomas A. Thrombosis and acute coronary-artery lesions in sudden cardiac ischemic death. *N Engl J Med*. 1984;310:1137-1140.
10. Burke AP, Kolodgie FD, Farb A, Weber D, Virmani R. Morphological predictors of arterial remodeling in coronary atherosclerosis. *Circulation*. 2002;105:297-303.
11. Achenbach S, Ropers D, Hoffmann U, et al. Assessment of coronary remodeling in stenotic and nonstenotic coronary atherosclerotic lesions by multidetector spiral computed tomography. *J Am Coll Cardiol*. 2004;43:842-847.
12. Motoyama S, Kondo T, Sarai M, et al. Multislice computed tomographic characteristics of coronary lesions in acute coronary syndromes. *J Am Coll Cardiol*. 2007;50:319-326.
13. Motoyama S, Sarai M, Harigaya H, et al. Computed tomographic angiography characteristics of atherosclerotic plaques subsequently resulting in acute coronary syndrome. *J Am Coll Cardiol*. 2009;54:49-57.
14. Kröner ES, van Velzen JE, Boogers MJ, et al. Positive remodeling on coronary computed tomography as a marker for plaque vulnerability on virtual histology intravascular ultrasound. *The American Journal of Cardiology*. 2011;107:1725-1729.
15. Fuster V, Moreno PR, Fayad ZA, Corti R, Badimon JJ. Atherothrombosis and high-risk plaque: part I: Evolving concepts. *J Am Coll Cardiol*. 2005;46:937-954.
16. Fuster V, Fayad ZA, Moreno PR, Poon M, Corti R, Badimon JJ. Atherothrombosis and high-risk plaque: part II: Approaches by noninvasive computed tomographic/magnetic resonance imaging. *J Am Coll Cardiol*. 2005;46:1209-1218.
17. Schmid M, Pflederer T, Jang IK, et al. Relationship between degree of remodeling and CT attenuation of plaque in coronary atherosclerotic

- lesions: an in-vivo analysis by multi-detector computed tomography. *Atherosclerosis*. 2008;197:457-464.
18. Nissen SE, De Franco AC, Tuzcu EM, Moliterno DJ. Coronary intravascular ultrasound: diagnostic and interventional applications. *Coron Artery Dis*. 1995;6:355-67.
19. Yamagishi M, Terashima M, Awano K, Kijima M, Nakatani S. Morphology of vulnerable coronary plaque: insights from follow-up of patients examined by intravascular ultrasound before an acute coronary syndrome. *J Am Coll Cardiol*. 2000;31;35:106-111.
20. Raffel OC, Merchant FM, Tearney GJ, et al. In vivo association between positive coronary artery remodelling and coronary plaque characteristics assessed by intravascular optical coherence tomography. *Eur Heart J*. 2008;29:1721-1728.